
Emergent Pelvic Fixation in Patients with Exsanguinating Pelvic Fractures

Martin A Croce, MD, FACS, Louis J Magnotti, MD, FACS, Stephanie A Savage, MD, George W Wood II, MD, FACS, Timothy C Fabian, MD, FACS

- BACKGROUND:** An alternative to embolization or external pelvic fixation (EPF) in patients with multiple pelvic fractures and hemorrhage is a pelvic orthotic device (POD), which may easily be placed in the resuscitation area. Little published information is available about its effectiveness. This study evaluated the efficacy of the POD compared with EPF in patients with life-threatening pelvic fractures.
- STUDY DESIGN:** We evaluated patients with blunt pelvic fractures over a 10-year period. Inclusion required multiple pelvic fractures with vascular disruption and severe retroperitoneal hematoma, open book fracture with symphysis diastasis, or sacroiliac disruption with vertical shear. Patients with EPF were compared with those in whom a POD was used. Outcomes included transfusions, hospital stay, and mortality.
- RESULTS:** There were 3,359 patients with pelvic fractures who were admitted: 186 (6%) met entry criteria; 93 had EPF and 93 had POD. There were no differences in age or shock severity. Both 24-hour (4.9 versus 17.1 U, $p < 0.0001$) and 48-hour transfusions (6.0 versus 18.6 U, $p < 0.0001$) were reduced with POD. Twenty-three percent of each group underwent pelvic angiography, and 24-hour transfusion amounts for those patients were also reduced with POD (9.9 versus 21.5 U, $p < 0.007$). Hospital length of stay (16.5 versus 24.4 days, $p < 0.03$) was less with POD. Although there was decreased mortality with POD (26%) versus EPF (37%), it was not statistically significant ($p = 0.11$).
- CONCLUSIONS:** The therapeutic shift to POD has substantially reduced transfusion requirements and length of hospital stay, and has reduced mortality in patients with unstable pelvic fractures. POD has made a major contribution to the care of critically injured patients with the most severe pelvic fractures. (*J Am Coll Surg* 2007;204:935–942. © 2007 by the American College of Surgeons)
-

Traumatic disruption of the pelvic ring is a major cause of life-threatening hemorrhage.^{1–7} The vascular anatomy of the pelvis, coupled with the bulk of cancellous bone, can account for exsanguinating hemorrhage after severe pelvic fractures. Early stabilization, as with other fractures, is a tenet of management, but adequate fracture stabilization of the pelvis is difficult.

Various methods of pelvic fracture stabilization have been described. These include inflatable pneumatic anti-shock garments,^{1,2,8} operative external fixation,^{3,6,9–12} pelvic wrapping with a sheet,¹³ and external orthotic devices.^{14,15}

Competing Interests Declared: None.

Presented at the Southern Surgical Association 118th Annual Meeting, West Palm Beach, FL, December 2006.

Received December 5, 2006; Accepted January 24, 2007.

From the Department of Surgery, University of Tennessee Health Science Center, Memphis, TN.

Correspondence address: Martin A Croce, MD, Department of Surgery, 956 Court Ave, #E226, Memphis, TN 38163.

At our institution, we have historically used emergent external pelvic fixation (EPF) in patients with exsanguinating pelvic fractures for stabilization. Recently, we have used a pelvic orthotic device (POD) because of its perceived efficacy and ease of application. The purpose of this study was to compare outcomes in patients initially managed with either EPF or POD who have unstable, life-threatening pelvic fractures.

METHODS

Patients admitted over a 10-year period to the Presley Regional Trauma Center in Memphis, TN with fractures of the pelvic ring after blunt trauma were identified from the trauma registry. Study inclusion required multiple pelvic ring fractures associated with vascular disruption and severe retroperitoneal hematoma, open book fracture with symphysis diastasis, or sacroiliac disruption with vertical shear (all anterior-posterior compression fractures II or III). Patients meeting these criteria underwent emergent

Abbreviations and Acronyms

AIS	=	Abbreviated Injury Score
EPF	=	external pelvic fixation
PASG	=	pneumatic antishock garments
POD	=	pelvic orthotic device
VAP	=	ventilator associated pneumonia

stabilization with an anterior frame (EPF) or a pelvic orthotic device (POD, T-POD, Cybertech Medical).

All patients were evaluated by the trauma team in the resuscitation area. If initial assessment revealed an unstable pelvic fracture and the patient was hemodynamically labile, emergent stabilization was performed. Early in the study series, EPF was used. Briefly, anterior fixation was accomplished with pins placed in the anterior superior iliac spine and stabilized with crossing bars. This was usually performed in the operating room. Abdominal evaluation included physical examination, supraumbilical peritoneal lavage, abdominal ultrasonography, or a combination of these. Later in the series, the POD was placed immediately on recognition of the unstable pelvis. After pelvic stabilization, additional hemodynamic instability mandated laparotomy for patients with a positive ultrasound or grossly positive lavage. If the patient had negative abdominal studies and no other obvious extrapelvic source of hemorrhage, pelvic angiography was performed.

Outcomes measured were resuscitative transfusions (blood transfused in the resuscitation area), and total blood transfusions at 24 and 48 hours. Hospital length of stay and mortality were also analyzed. Ventilator associated pneumonia (VAP) was evaluated as a marker of infectious morbidity. All instances of VAP were diagnosed using fiberoptic bronchoscopy with quantitative cultures of the bronchoalveolar lavage effluent, with $> 10^5$ organisms as the diagnostic threshold.

Discrete variables were compared using chi-squared analysis (JMP, version 5.0). Continuous variables were compared using the unpaired *t*-test. Statistical significance was set at $p < 0.05$.

RESULTS

Over the study period, there were 30,048 patients with blunt trauma admitted to the trauma center, 3,359 (11%) of whom had pelvic fractures. Of these patients with pelvic fractures, there were 241 (7%) patients with multiple pelvic ring fractures, open book fractures, or sacroiliac disruption, and 186 of these (77%) underwent emergent external stabilization for their pelvic fractures. Motor vehicle crash was the most common injury mechanism (60%), followed by motorcycle or all-terrain vehicle crash (15%), industrial

Table 1. Characteristics of the Study Population

Variable	POD	EPF	p Value
n	93	93	
Male, n	56	67	0.09
Female, n	37	26	
Age, y	37.6	36.3	0.58
ISS	33.6	38.6	0.02
SBP, mmHg	112.5	101.6	0.07
BE, meq/L	-7.15	-8.50	0.14
GCS	11.9	11.2	0.33
RTS	9.7	8.8	0.13

BE, admission base excess; EPF, external pelvic fixation; GCS, Glasgow Coma Scale score; ISS, Injury Severity Score; POD, pelvic orthotic device; RTS, Revised Trauma Score; SBP, admission systolic blood pressure.

accident (10%), auto-pedestrian accident (9%), and falls (6%). Pronounced associated injuries (Abbreviated Injury Score [AIS] > 2) were seen in all but one patient. Abdominal injuries were most commonly seen (64%), followed by chest injuries (54%) and head injuries (21%).

The study population was comprised of 93 patients (50%) who underwent POD placement and 93 (50%) who underwent EPF. Their characteristics are shown in Table 1. Patients were well matched with respect to gender, age, and severity of shock (as measured by Injury Severity Score, systolic blood pressure, and base excess) on admission. Those managed with EPF had higher Injury Severity Scores than those managed with POD, which was, in part, because of higher abdominal AIS in the EPF group (2.9 versus 1.6; $p < 0.001$). Despite this difference, laparotomy rates were similar between groups (28% for EPF versus 23% for POD; $p = 0.4$).

Table 2 shows transfusion-related outcomes. Patients treated with POD had notably fewer resuscitation transfusions despite the equivalent severities of shock on presentation. Immediate POD placement also substantially reduced transfusions at both 24 and 48 hours when compared with EPF. This is likely because of quicker hemorrhage control in patients with POD placement, reducing both initial and subsequent transfusion requirements.

Pelvic angiography was performed in 23% of each group. Not surprisingly, overall transfusions were higher in

Table 2. Outcomes for Study Groups

Variable	POD	EPF	p Value
Resuscitative, Tx	2.0	3.5	0.004
24 h, Tx	4.9	17.1	0.008
48 h, Tx	5.6	18.6	0.008
Pelvic angiogram, n	21	21	
Mortality, %	26	37	0.11

EPF, external pelvic fixation; POD, pelvic orthotic device; Tx, units of blood transfused.

Table 3. Comparison of Survivors and Nonsurvivors

Variable	Alive	Dead	p Value
n	128	58	
Age, y	36.0	39.0	0.23
ISS	31.5	46.2	0.0001
SBP, mmHg	116.8	85.8	0.0001
BE, meq/L	-6.2	-11.4	0.0001
GCS	12.9	8.6	0.0001
RTS	10.4	6.7	0.0001
Resuscitative, Tx	1.7	5.0	0.0001
24 h, Tx	7.1	19.7	0.0001
48 h, Tx	8.3	21.1	0.0001
Hospital stay, d	28.2	3.9	0.0001

BE, admission base excess; EPF, external pelvic fixation; GCS, Glasgow Coma Scale score; ISS, Injury Severity Score; POD, pelvic orthotic device; RTS, Revised Trauma Score; SBP, admission systolic blood pressure; Tx, units of blood transfused.

this patient subset. But both 24- and 48-hour transfusions were considerably higher in the EPF group (21.5 and 25.7 U versus 9.9 and 12.0 U for POD, respectively; each $p < 0.008$), underscoring the importance of early hemorrhage control.

VAP was used as an objective marker for infectious morbidity. The VAP rate was considerably higher in the EPF group (33% versus 10%; $p < 0.0001$). This difference may be due, in part, to slightly more severe chest injury in the EPF group (chest AIS 2.0 versus 1.6; $p = 0.3$), but this difference was not statistically significant. A more likely reason for increased VAP in the EPF patients is the increased amount of blood transfused. Overall hospital stays were notably longer in the EPF patients (24.4 versus 16.5 days; $p < 0.03$). This is likely due, in part, to the increased infectious morbidity in the EPF group.

Overall mortality was 31%. There was no marked mortality difference between groups (37% for EPF versus 26% for POD; $p = 0.1$). Not surprisingly, those who died were in more profound shock at presentation, more severely injured, and had higher transfusion requirements (Table 3). Patients who died were analyzed by study group (Table 4). Interestingly, those who died in the POD group had fewer transfusions at 24 and 48 hours compared with those in the EPF group (8.8 and 9.0 versus 27.4 and 29.7; $p < 0.0001$). The hospital stay for POD was also shorter (2.1 versus 5.2 days; $p < 0.06$), suggesting that the POD patients were more likely to have died from other injuries unrelated to their pelvic fracture. Indeed, the head and neck AIS for POD was 2.5 compared with 1.2 for EPF ($p < 0.03$).

DISCUSSION

The concept of fracture stabilization to reduce hemorrhage and initiate healing is not unique to modern medicine. The

Table 4. Comparison of Nonsurvivors by Study Group

Variable	POD	EPF	p Value
n	24	34	
Age, y	41.4	37.3	0.39
ISS	48.9	44.3	0.17
SBP, mmHg	82	88.7	0.58
BE, meq/L	-11.3	-11.4	0.95
GCS	8.3	8.8	0.71
RTS	6.4	6.9	0.64
Resuscitative, Tx	4.3	5.6	0.19
48 h, Tx	9.0	29.7	0.0001
24 h, Tx	8.8	27.4	0.0001
Hospital stay, d	2.1	5.2	0.06

BE, admission base excess; EPF, external pelvic fixation; GCS, Glasgow Coma Scale score; ISS, Injury Severity Score; POD, pelvic orthotic device; RTS, Revised Trauma Score; SBP, admission systolic blood pressure; Tx, units of blood transfused.

ancient Hindus used bamboo splints to treat fractures. The ancient Egyptians used wooden splints cushioned with linen, and added roller bandages for stabilization: "I have broken the arm of Pharaoh. . .to put a roller, that it be bound up and wax strong, that it hold the sword."¹⁶ This basic concept of fracture stabilization has not changed for thousands of years. Fortunately, stabilization of long bone fractures can readily be accomplished, resulting in hemorrhage reduction and pain control. Unfortunately, the pelvic anatomy is not conducive to rapid, effective splinting. The large amount of cancellous bone and surrounding vascular anatomy allows for ongoing hemorrhage after severe pelvic fractures. Exsanguinating hemorrhage is not uncommon among patients with multiple pelvic fractures, open book fractures, and sacroiliac disruption, with some reported mortality rates exceeding 40%.^{5,17-19} It is clear that prompt appropriate therapy may be lifesaving.

Early operative management of patients with exsanguinating pelvic fractures was first described 35 years ago by Hawkins and colleagues.²⁰ In their study, 35 patients with severe pelvic fractures required laparotomy. Massive hemorrhage accounted for 20% mortality. The authors recommended avoiding the pelvic hematoma, discouraged hypogastric artery ligation, and suggested transfusion of 20 U of blood before performing laparotomy. Generally, laparotomy for pelvic fracture bleeding has been avoided since then, although there are still some proponents.⁴ A recent method of retroperitoneal packing has been described in two patients, but widespread application is uncertain.²¹

There are two methods for pelvic fracture stabilization: internal and external. Internal techniques are usually reserved for definitive repair and are not typically used in patients with exsanguinating hemorrhage. There are basically two types of external fixation: invasive and noninva-

sive. Invasive methods include anterior and posterior fixators, and are usually placed in the operating room, but may be applied in the resuscitation area.

The posterior fixator functions as a C-clamp and allows rapid provisional pelvic stabilization.^{4,11} There is secure bony attachment in either the posterior ilium^{4,9} or the greater trochanters.¹¹ Both methods are effective at achieving pelvic stabilization and reduction in pelvic volume, and are associated with approximately 30% mortality. But there are potentially serious complications associated with the use of a C-clamp, including ilium perforation, pin dislodgement involving the greater sciatic notch, and fragment displacement.^{22,23} In addition, these severely injured patients frequently have associated soft tissue wounds that may preclude sterile placement. Patients with Morel-Lavallee soft tissue injuries and fracture hematomas are at extremely high risk for infection after C-clamp placement. So although it is an effective method for emergent pelvic stabilization, enthusiasm for its use has waned considerably because of its potential for devastating complications.

Anterior fixation is another invasive means for emergent stabilization. This method avoids the problems with pin placement through the fracture hematoma and the posterior pelvic elements. It is also an effective way to control venous bleeding in both laboratory models²⁴ and clinical trials.^{5,10} Pins are placed in the anterior superior iliac spine and then stabilized with crossing bars. The main issues with this fixation method are bar placement and application location. The bars may restrict access to the abdomen. If laparotomy is required, the bars should be placed inferiorly. The fixator may be placed in the resuscitation area, but it is best placed in the operating room.

Given the logistic issues and complication potential of invasive emergent EPF, an efficacious noninvasive method would be ideal. This may be accomplished with the pneumatic antishock garment (PASG). Application of this device allows for circumferential stabilization of the severely fractured pelvis. Flint and colleagues¹ analyzed 40 patients with severe pelvic fractures, 10 of whom were immobilized with PASG. They reported no deaths in the patients treated with PASG, and a marked mortality reduction compared with historic controls. Other investigators have reported positive results in patients treated with PASG.^{6,12} The efficacy of PASG was improved when it was combined with a team approach for pelvic fracture management.^{2,6} These investigators independently demonstrated improved outcomes with a multimodal approach to patients with exsanguinating pelvic fractures. The combination of PASG, external fixation, and selective angiography proved beneficial in these severely injured patients. But PASG use, if not closely monitored, can lead to skin and

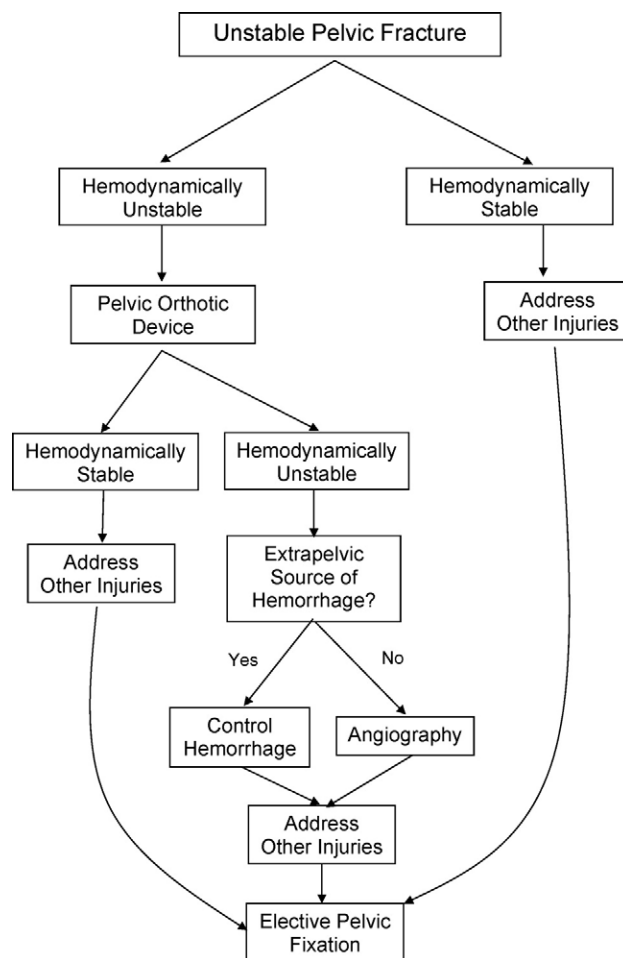


Figure 1. Clinical pathway for the management of patients with unstable pelvic fractures.

soft tissue necrosis. In addition, the garment is cumbersome and precludes access to the abdomen and lower extremities.

A POD is similar in concept to PASG in that it provides circumferential pressure. It may be easily placed in the resuscitation area, is noninvasive, and requires no anesthesia. The POD used in this study was effective in controlling hemorrhage in patients with unstable, complex pelvic fractures. Those initially managed with the POD had similar clinical markers of hemorrhagic shock (admission systolic blood pressure and base excess) when compared with those managed with external fixation. But patients managed with POD required considerably fewer blood transfusions, had fewer episodes of VAP, and left the hospital sooner than those with EPF.

Why was the POD so effective when compared with EPF? It is possible that the POD is a more effective method of fracture fixation, allowing for a stable and controlled pelvic volume. Most likely, it is the rapidity with which the

POD can be effectively applied. The pelvic fracture is immediately stabilized. Even in the best hands, EPF may take at least 30 to 60 minutes, especially if performed in the operating room. This delay can account for ongoing hemorrhage and the requirement for increased blood transfusions. Increasing transfusions are also independently associated with increased infectious morbidity, especially VAP.²⁵

Once applied, after POD or EPF, additional hemodynamic instability indicates either an extrapelvic source of hemorrhage or pelvic arterial hemorrhage. In this study, equal numbers of patients underwent pelvic angiography, suggesting similar efficacy for controlling fracture site and pelvic venous hemorrhage. Our angiogram rate was similar to that of the Denver group,³ but the reported angiography rates vary widely.^{7,26-28}

Figure 1 demonstrates our institutional clinical pathway for management of patients with exsanguinating pelvic fractures. The POD is an important bridge to definitive fracture management. Its use has been invaluable in the rapid control of life-threatening pelvic hemorrhage, affording the opportunity for elective operative fixation (either internal or external) in a more controlled fashion.

Author Contributions

Study conception and design: Croce, Wood, Fabian

Acquisition of data: Croce, Savage

Analysis and interpretation of data: Croce, Magnotti, Fabian

Drafting of manuscript: Croce, Magnotti, Fabian

Critical revision: Croce, Magnotti, Fabian

REFERENCES

- Flint LM Jr, Brown A, Richardson JD, Polk JC. Definitive control of bleeding from severe pelvic fractures. *Ann Surg* 1979;189:709-716.
- Flint L, Babikian G, Anders M, et al. Definitive control of mortality from severe pelvic fracture. *Ann Surg* 1990;211:703-707.
- Biffi WL, Smith WR, Moore EE, et al. Evolution of a multidisciplinary clinical pathway for the management of unstable patients with pelvic fractures. *Ann Surg* 2001;233:843-850.
- Ertal W, Keel M, Eid K, et al. Control of severe hemorrhage using C-clamp and pelvic packing multiply injured patients with pelvic ring disruption. *J Ortho Trauma* 2001;15:468-474.
- Evers BM, Cryer HM, Miller FB. Pelvic fracture hemorrhage. *Arch Surg* 1989;124:422-424.
- Moreno C, Moore EE, Rosenberger A, Cleveland HC. Hemorrhage associated with major pelvic fracture: a multispecialty challenge. *J Trauma* 1986;26:987-994.
- Stephen DJG, Kreder HF, Day AC, et al. Early detection of arterial bleeding in acute pelvic trauma. *J Trauma* 1999;47:638.
- Brotman S, Soderstrom CA, Oster-Granite M, et al. Management of severe bleeding in fractures of the pelvis. *Surg Gynecol Obstet* 1981;153:823-826.
- Heini PF, Witt J, Ganz R. The pelvic C-clamp for the emergency treatment of unstable pelvic ring injuries. A report on clinical experience of 30 cases. *Injury* 1996;(Suppl 1):A38-A45.
- Waikukul S, Harnroongroj T, Vanadurongwan V. Immediate stabilization of unstable pelvic fractures versus delayed stabilization. *J Med Assoc Thai* 1999;82:637-642.
- Archdeacon MT, Hiratzka J. The trochanteric C-clamp for provisional pelvic stability. *J Orthop Trauma* 2006;20:47-51.
- Batalden DJ, Wickstrom PH, Ruiz E, Gustilo RB. Value of the G suite in patients with severe pelvic fractures. *Arch Surg* 1974;109:326-328.
- Roult MLC, Falicov A, Woodhouse E, Schildhauer TA. Circumferential pelvic anti-shock sheeting: a temporary resuscitation aid. *J Orthop Trauma* 2002;16:45-48.
- Krieg JC, Mohr M, Ellis TJ, et al. Emergent stabilization of pelvic ring injuries by controlled circumferential compression: a clinical trial. *J Trauma* 2005;59:659-664.
- Bottlang M, Krieg JC, Mohr M, et al. Emergent management of pelvic ring fractures with use of circumferential compression. *J Bone Joint Surg Am* 2002;84:43-47.
- Holy Bible. Ezekiel 30;21.
- Eastridge BJ, Starr A, Minei JP, O'Keefe GE. The importance of fracture pattern in guiding therapeutic decision-making in patients with hemorrhagic shock and pelvic ring disruptions. *J Trauma* 2002;53:446-451.
- Rothenberger D, Fischer R, Strate R, et al. Mortality associated with pelvic fractures. *Surgery* 1978;84:356-362.
- Cryer H, Miller F, Evers B. Pelvic fractures classification: correlation with hemorrhage. *J Trauma* 1988;28:973-980.
- Hawkins L, Pomerantz M, Eisman B. Laparotomy at the time of pelvic fracture. *J Trauma* 1970;10:619-623.
- Smith WR, Moore EE, Osborn P, et al. Retroperitoneal packing as a resuscitation technique for hemodynamically unstable patients with pelvic fractures: report of two representative cases and a description of technique. *J Trauma* 2005;59:1510-1514.
- Bottlang M, Simpson T, Sigg J, et al. Noninvasive reduction of open-book pelvic fractures by circumferential compression. *J Orthop Trauma* 2002;16:367-373.
- Pohlemann T, Braune C, Gansslen A, et al. Pelvic emergency clamps: anatomic landmarks for a safe primary application. *J Orthop Trauma* 2004;18:102-105.
- Grimm MR, Vrahas MS, Thomas KA. Pressure-volume characteristics of the intact and disrupted pelvic retroperitoneum. *J Trauma* 1998;44:454-459.
- Croce MA, Tolley EA, Claridge JA, Fabian TC. Transfusions result in pulmonary morbidity and death after a moderate degree of injury. *J Trauma* 2005;59:19-23.
- Poole GV, Ward EF, Muakkassa FF, et al. Pelvic fracture from major blunt trauma. Outcome is determined by associated injuries. *Ann Surg* 1991;213:532-539.
- Agolini SF, Kamalesh S, Jaffe J, et al. Arterial embolization is a rapid and effective technique for controlling pelvic fracture hemorrhage. *J Trauma* 1997;43:395-399.
- Miller PR, Moore PS, Mansell E, et al. External fixation or arteriogram in bleeding pelvic fracture: initial therapy guided by markers of arterial hemorrhage. *J Trauma* 2003;54:437-443.